

Rapidly progressing glioblastoma resembling brain abscess in leukemia

George A. ALEXIOU¹, Spyridon TSIOURIS², Athanasios P. KYRITSIS³, Konstantinos S. POLYZOUIDIS¹,
Spyridon VOULGARIS¹ and Andreas D. FOTOPOULOS²

¹Department of Neurosurgery, ²Department of Nuclear Medicine, ³Department of Neurology, University Hospital of Ioannina, Ioannina, Greece

Abstract

A 63-year-old man with a history of chronic lymphocytic leukemia and a prosthetic aortic valve was hospitalized because of a mastoiditis, complicated by meningitis and epileptic seizures. Two weeks later he developed a lesion in the right temporal lobe. A brain abscess was suspected. However, after treatment his clinical condition failed to improve. ^{99m}Tc-Tetrofosmin brain SPECT was performed and revealed substantially increased tracer uptake. Due to the patient's clinical deterioration, surgery was considered most appropriate. Histopathology established the diagnosis of glioblastoma multiforme. This case suggests a note of caution in every case of a rapidly evolving space-occupying lesion independently of the patient's previous history.

Key words: SPECT; imaging of; infections CNS; glioblastoma, brain abscess, ^{99m}Tc-Tetrofosmin.

Introduction

The differential diagnosis of a brain lesion that shows a ring-like enhancement pattern on computed tomography (CT) and magnetic resonance imaging (MRI) may be difficult and typically includes necrotic tumour and pyogenic brain abscess. A systematic approach and assessment of the patient's history may provide clues to narrow the differential. Discrimination between these two entities is of paramount importance, since they require completely different therapeutic approaches and they carry diverse prognosis. Herewith we report on an unusual case of a rapidly evolving glioblastoma mimicking a brain abscess, in an immunocompromised patient.

Case history

A 63-year-old man was referred to our hospital complaining of nausea and gait disorder of two months duration. The patient had been diagnosed with and was treated for chronic lymphocytic leukemia the past 5 years; he also had cardiac surgery to replace the aortic valve with a prosthesis 15 months earlier. Two months prior to his initial

referral, he had an episode of mastoiditis on the left side, for which he was hospitalized and treated by myringotomy with tympanostomy and tube insertion. His condition was then complicated by meningitis and epileptic seizures, for which he underwent a CT scan. This demonstrated a normal brain parenchyma (Fig. 1A); it also supported the presence of mastoiditis, demonstrating fluid-filled middle ears and mastoids, as well as fluid accumulation in the frontal, ethmoidal, and maxillary sinuses. The patient received the proper antibiotic treatment, his condition improved and he was discharged twelve days later.

Two weeks later he complained of right otalgia with otorrhea and acute otitis media was diagnosed. The neurological examination was unremarkable. A subsequent brain CT scan at that time revealed a space-occupying lesion 14 mm in diameter in the posterior part of the right temporal lobe (Fig. 1B). Considering his preceding history and the fact that on the CT scan the brain lesion appeared to develop in a fortnight, an abscess was the most likely diagnosis. The patient was treated accordingly with intravenous antibiotics. However, after ten days' hospitalization and treatment his clinical condition failed to improve. On a follow-up CT scan the brain lesion had increased in size, developed a peripheral ring-enhancing pattern following the administration of contrast medium, and was surrounded by edema (Fig. 1C).

The clinical course and the radiographic aggravation suggested the possibility of a brain tumor. In order to evaluate the metabolic status of the lesion, we decided to perform a brain scintigraphic study using the tumor-seeking radiopharmaceutical technetium-99m Tetrofosmin (^{99m}Tc-TF). The single-photon emission computed tomographic (SPECT) study revealed substantially increased tracer uptake in a region spatially corresponding to the brain lesion on the last CT scan (Fig. 2). This finding denoted the presence of a lesion of strong metabolic activity, which was more compatible with the presence of a brain neoplasm.

Due to the patient's clinical deteriorating and in light of the aforementioned morphologic and

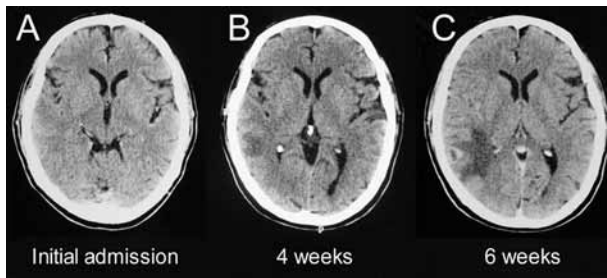


FIG. 1. — A : Contrast enhanced CT. No unusual findings ; B : 4 weeks later a lesion in the right temporal lobe appeared ; C : follow up CT two weeks later demonstrated the lesion with a thick irregular ring of enhancement.

metabolic findings, surgery to excise the lesion was considered most appropriate. Histopathology established the diagnosis of glioblastoma multiforme ; the lesion's cellular proliferation rate (Ki-67) – as immunohistologically assessed by the MIB-1 labeling index – was 10%. Flow cytometry of the excised tumor revealed aneuploidy and an 11% of cells being in the S-phase of the cell cycle.

Discussion

Immunocompromised hosts are vulnerable to several pathogens, with intracranial infections like meningitis and brain abscess being major concerns in the treatment of these patients. Otologic and rhinosinugenic diseases are well-known precursors of brain abscess and in the majority of cases the lesion is singular (Yen P. T. *et al.*, 1995). Infection may spread by local osteomyelitis, or by phlebitis of the emissary veins. The temporal lobes are commonly affected in brain abscesses of otogenic origin. In the initial phase of infection the brain tissue reacts to the pathogen by developing local cerebritis and subsequently an encapsulated brain abscess is formed within 10-14 days (Holmes T. M. *et al.*, 2004 ; Karampekios S. *et al.*, 2005 ; Mathisen G. E. *et al.*, 1997).

Laboratory tests are of limited help in establishing a diagnosis. Lumbar puncture is generally not recommended, because the pathogen is rarely found, while there is always a risk of herniation, mainly in extended lesions. CT and MRI offer valuable information regarding lesion morphology, while imaging after the administration of contrast or paramagnetic media attempts to characterize the lesions' benign or malignant character. Nonetheless, these imaging modalities cannot always discriminate between abscess, astrocytic tumor, malignant lymphoma, metastasis, or resolving hematoma, since all these pathologies may be associated with peripheral, ring-like contrast enhancement. Several advanced MRI techniques have been evaluated towards this scope. Diffusion-weighted imaging and apparent diffusion coefficient have been used to distinguish brain abscesses from cystic or necrotic brain tumors with

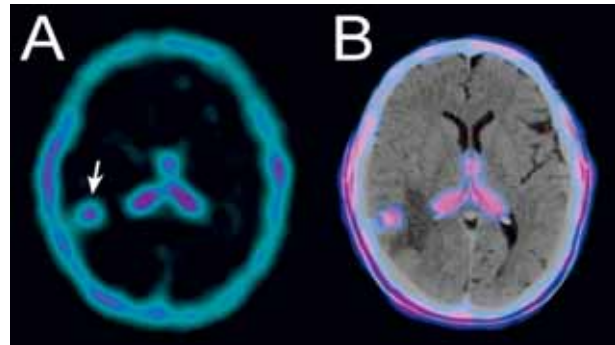


FIG. 2. — A : ^{99m}Tc -TF brain SPECT shows a lesion with strong tracer uptake in the right temporal lobe ; B : ^{99m}Tc -TF brain SPECT superimposed on CT image.

promising results (Chang S. C. *et al.*, 2002). Additionally, magnetic resonance spectroscopy may assist in obtaining the correct preoperative diagnosis, especially when combined with diffusion-weighted imaging (Lai P. H. *et al.*, 2002). On the other hand, positron emission tomography (PET) with various tracers was not able to distinguish reliably between benign nonneoplastic lesions and malignant gliomas (Floeth F. W. *et al.*, 2006 ; Sasaki M. *et al.*, 1990).

The use of SPECT radiopharmaceuticals has been introduced before the PET era with good results and is gaining popularity again. Thallium-201 (^{201}Tl) was one of the first tracers extensively used, while technetium-99m-labeled compounds have also been studied and proved advantageous over ^{201}Tl , due to the 140 keV γ -ray energy and high photon flux resulting in higher spatial resolution, with significantly lower radiation burden to the patient (Choi J. Y. *et al.*, 2000). ^{99m}Tc -TF is a lipophilic diphosphine routinely used for myocardial perfusion imaging. Furthermore, it has been found to display tumor-seeking properties, thus proving useful in depicting high proliferative central nervous system lesions. It normally does not cross the blood-brain barrier, therefore any uptake in the brain parenchyma can be readily recognized. We recently reported that ^{99m}Tc -TF SPECT could reliably distinguish glioma recurrence from radiation necrosis and we also evaluated the relationship between glioma and meningioma proliferation (as expressed by Ki-67) and the uptake of ^{99m}Tc -TF. In both cases we verified a strong positive linear correlation between tracer uptake and Ki-67 expression (Alexiou G. A. *et al.*, 2007). Furthermore, we showed that ^{99m}Tc -TF SPECT could play a role in differentiating neoplastic from intracerebral hemorrhage (Alexiou G. A. *et al.*, 2006). A site of infection and inflammation in the brain, like a brain abscess, exhibits increased tissue metabolism, it is therefore expected to accumulate the radiotracer in higher amounts than the surrounding normal brain parenchyma.

The proliferation status in a brain abscess could be somewhat increased compared to the surrounding brain, but it does not reach the levels of

glioblastoma multiforme. In accordance with this, there have been reports that a brain abscess may be imaged by ^{201}Tl , but it displays a significantly poorer tracer accumulation, as compared to a brain tumor (Kinuya K. *et al.*, 2002 ; Taki S. *et al.*, 1999). The lesion excised from our patient had a Ki-67 level of 10%, a finding that correlated with the radiotracer uptake intensity recorded at the SPECT study.

An accurate diagnosis is of paramount importance, though, since each of these entities has different treatment and prognosis. For example, corticosteroid therapy should be administered in patients with brain tumors preoperatively, but is contra-indicated in cases of brain abscess.

In the present case, a glioblastoma multiforme presented and developed in a rather unusual way, imitating a brain abscess. Our patient was immunosuppressed secondary to a hematological malignancy and recently suffered from mastoiditis with complicating meningitis. Furthermore, the lesion developed within the short period of four weeks following the meningitis episode. These attributes were initially considered as more in accordance with the diagnosis of abscess. Nevertheless, chronic lymphocytic leukemia is associated with an increased incidence of secondary neoplasms. Primary brain tumors are rarely seen, yet an increased risk relative to the general population has been observed (Pejsa V. *et al.*, 2005).

In the final analysis, this case illustrates that the possibility of a brain neoplasm should always be kept in mind, even in cases of rapidly evolving space-occupying lesions that resemble abscess and independently of the patient's previous history. Nevertheless, a brain tumor may resemble an abscess as well. An early differentiation is important because the prognosis of a brain abscess is better than that of a malignant brain tumor. Functional metabolic brain imaging by $^{99\text{m}}\text{Tc}$ -TF SPECT may prove useful in characterizing the metabolic status of any such lesion detected by morphologic imaging. It would be challenging to prospectively estimate the value of implementing this modality in the preoperative workup of similar cases, at least where CT or MRI findings are inconclusive.

REFERENCES

- ALEXIOU G. A., TSIOURIS S., GOUSSIA A., PAPADOPOULOS A., POLYZOUIDIS K. S., KYRITSIS A. P., FOTOPOULOS A. D. Evaluation of glioma proliferation by $^{99\text{m}}\text{Tc}$ -Tetrofosmin. *Neuro Oncol.*, 2008, **10** : 104-105.
- ALEXIOU G. A., FOTOPOULOS A. D., PAPADOPOULOS A., KYRITSIS A. P., POLYZOUIDIS K. S., TSIOURIS S. Evaluation of brain tumor recurrence by $^{99\text{m}}\text{Tc}$ -Tetrofosmin SPECT – A prospective pilot study. *Ann. Nucl. Med.*, 2007, **21** : 293-298.
- ALEXIOU G. A., TSIOURIS S., GOUSSIA A., PAPADOPOULOS A., POLYZOUIDIS K. S., KYRITSIS A. P., FOTOPOULOS A. D. $^{99\text{m}}\text{Tc}$ -Tetrofosmin Brain SPECT for the assessment of meningiomas. *Skull Base*, 2007, **17** : 7-8.
- ALEXIOU G. A., BOKHARHII J. A., KYRITSIS A. P., POLYZOUIDIS K. S., FOTOPOULOS A. D. Tc-99m Tetrofosmin SPECT for the differentiation of a cerebellar hemorrhage mimicking a brain metastasis from a renal cell carcinoma. *J. Neurooncol.*, 2006, **78** : 207-208.
- CHANG S. C. , LAI P. H., CHEN W. L., WENG H. H., HO J. T., WANG J. S., CHANG C. Y., PAN H. B., YANG C. F. Diffusion-weighted MRI features of brain abscess and cystic or necrotic brain tumors : comparison with conventional MRI. *Clin. Imaging*, 2002, **26** : 227-236.
- CHOI J. Y., KIM S. E., SHIN H. J., KIM B. T., KIM J. H. Brain tumor imaging with $^{99\text{m}}\text{Tc}$ -tetrofosmin : comparison with ^{201}Tl , $^{99\text{m}}\text{Tc}$ -MIBI, and ^{18}F -fluorodeoxyglucose. *J. Neurooncol.*, 2000, **46** : 63-70.
- FLOETH F. W., PAULEIT D., SABEL M., REIFENBERGER G., STOFFELS G., STUMMER W., ROMMEL F., HAMACHER K., LANGEN K. J. 18F-FET PET differentiation of ring-enhancing brain lesions. *J. Nucl. Med.*, 2006, **47** : 776-782.
- HOLMES T. M., PETRELLA J. R., PROVENZALE J. M. Distinction between cerebral abscesses and high-grade neoplasms by dynamic susceptibility contrast perfusion MRI. *AJR Am. J. Roentgenol.*, 2004, **183** : 1247-1252.
- KARAMPEKIOS S., HESSELINK J. Cerebral infections. *Eur. Radiol.*, 2005, **15** : 485-493.
- KINUYA K., OHASHI M., ITOH S., YAMAMOTO K., SAKAI S., KAKUDA K., NOBATA K., KATO N., TERAHARA S., TAKI S. Differential diagnosis in patients with ring-like thallium-201 uptake in brain SPECT. *Ann. Nucl. Med.*, 2002, **16** : 417-421.
- LAI P. H., HO J. T., CHEN W. L., HSU S. S., WANG J. S., PAN H. B., YANG C. F. Brain abscess and necrotic brain tumor : discrimination with proton MR spectroscopy and diffusion-weighted imaging. *AJNR Am. J. Neuroradiol.*, 2002, **23** : 1369-1377.
- MATHISEN G. E., JOHNSON J. P. Brain abscess. *Clin. Infect. Dis.*, 1997, **25** : 763-779.
- PEJSA V., GRGUREVIC I., PAZANIN L., LANG N., GRGUREVIC L., JAKSIC O. Multicentric glial brain tumors of a varying degree of differentiation in patient with chronic lymphocytic leukemia. *Am. J. Hematol.*, 2005, **79** : 50-53.
- SASAKI M., ICHIYA Y., KUWABARA Y., OTSUKA M., TAHARA T., FUKUMURA T., GUNASEKERA R., MASUDA K. Ringlike uptake of [18F]FDG in brain abscess : a PET study. *J. Comput. Assist. Tomogr.*, 1990, **14** : 486-487.
- TAKI S., KAKUDA K., KAKUMA K., KOBAYASHI K., OHASHI M., ITO S., YOKOYAMA M., ANNEN Y., TONAMI N. ^{201}Tl SPET in the differential diagnosis of brain tumours. *Nucl. Med. Commun.*, 1999, **20** : 637-645.
- YEN P. T., CHAN S. T., HUANG T. S. Brain abscess : with special reference to otolaryngologic sources of infection. *Otolaryngol. Head Neck Surg.*, 1995, **113** : 15-22.

George A. ALEXIOU, M.D.,
P.O. Box 103, Neohoropoulo,
Ioannina, 455 00 (Greece).
E-mail : alexiougrg@yahoo.gr